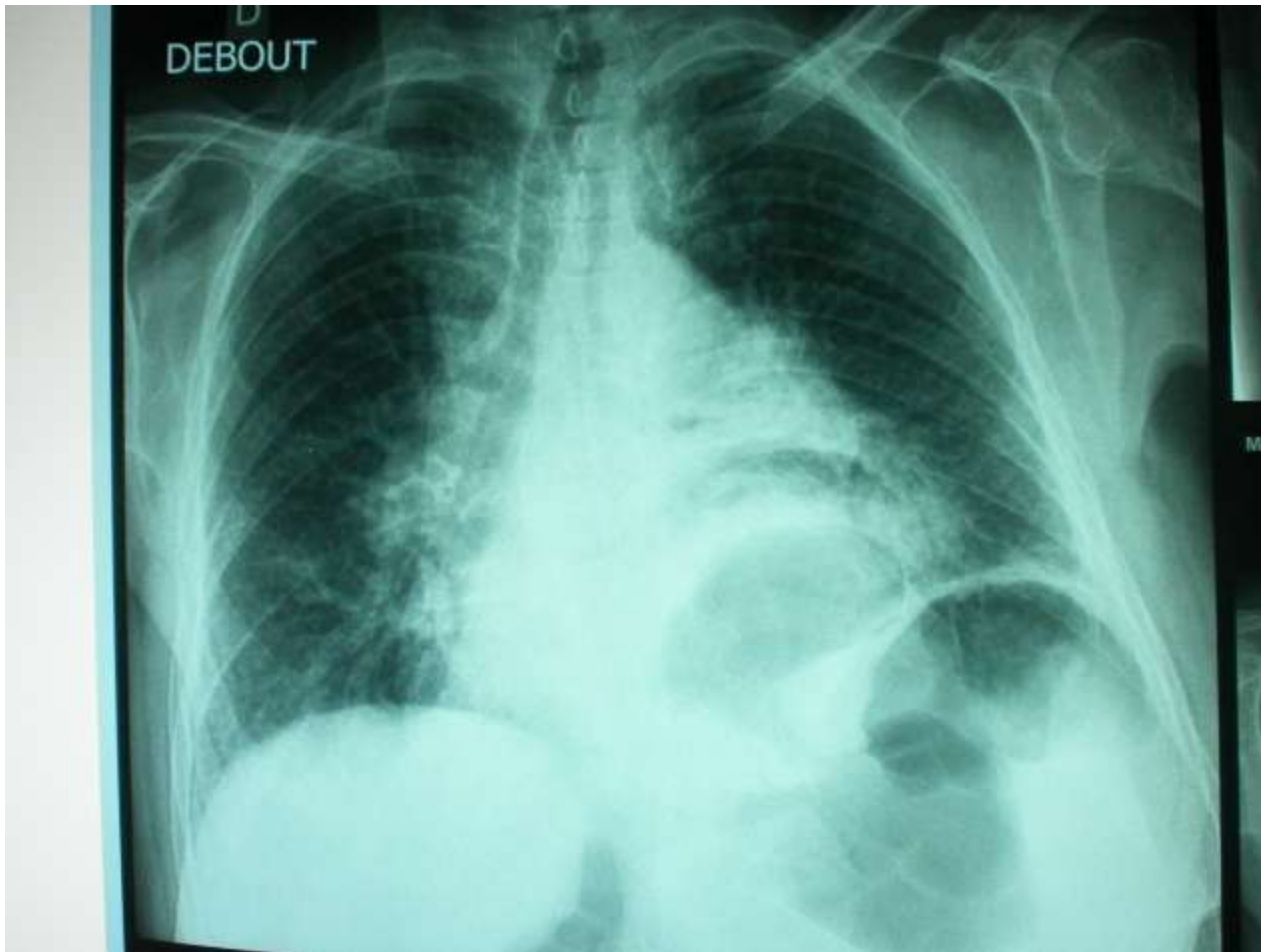
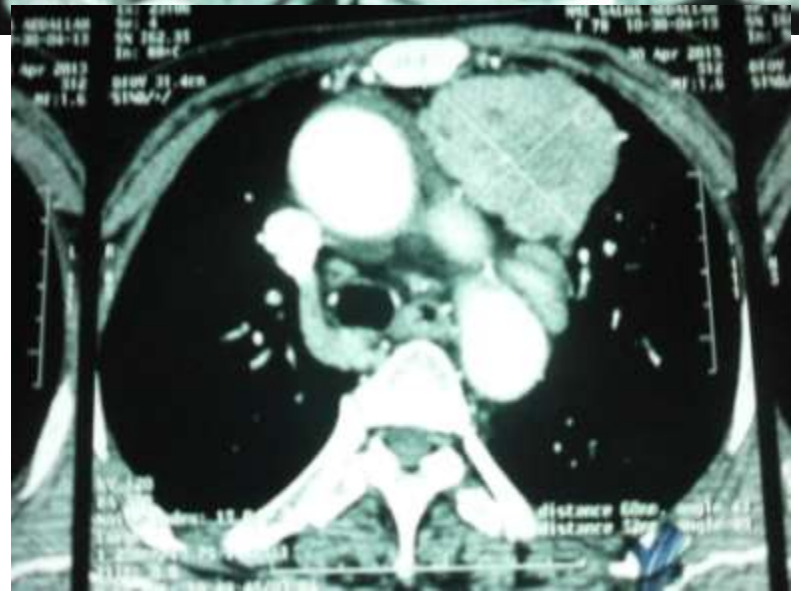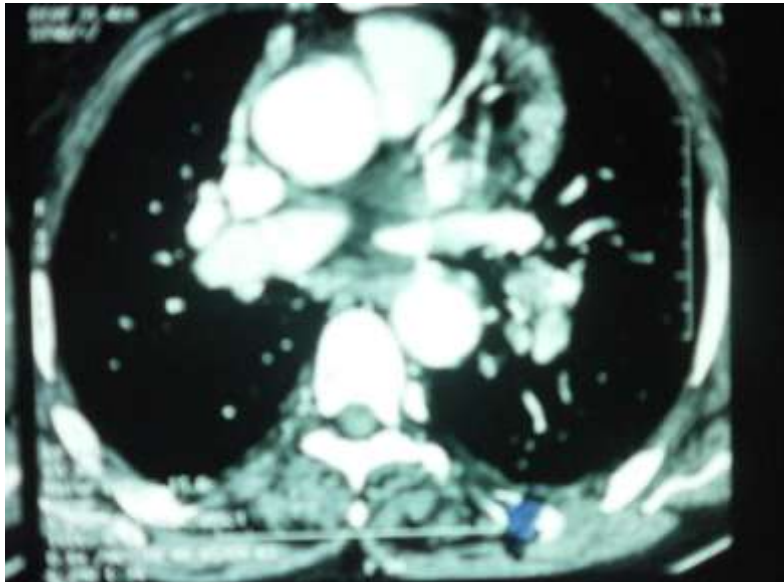
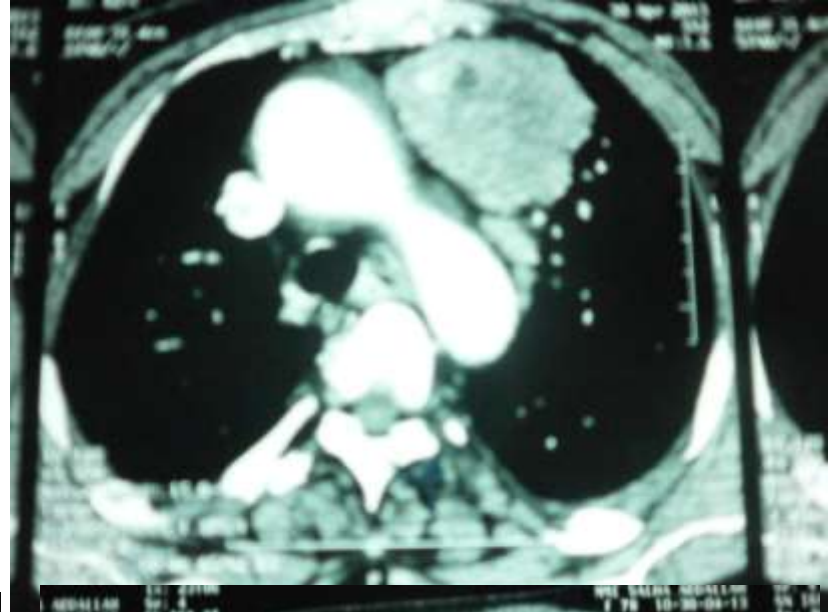
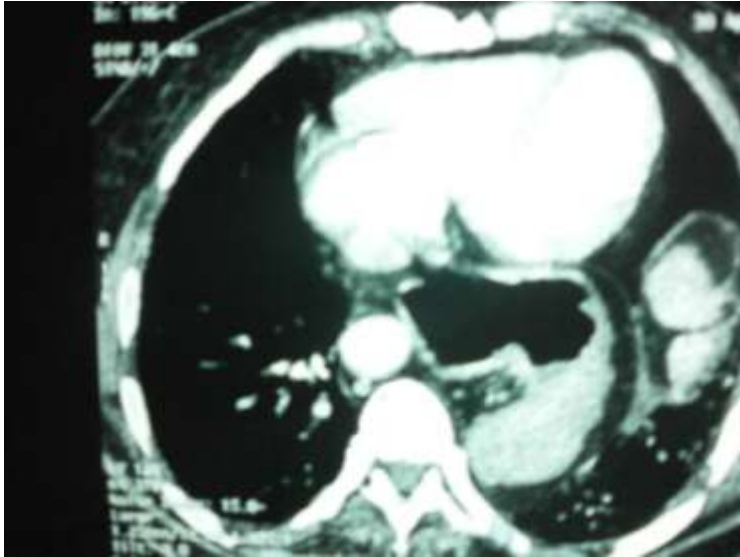


Mme Mabrouka... 77 ANS DYSPNEE DEPUIS 5ANS DYSPHAGIE AUX SOLIDE DEPUIS 11NS



Scanner thoracique:HERNIE HIATALE ET
« TUMEUR MEDISATINALE »..aspect hétérogène..contenu gastrique



HERNIE HIATALE

Forme pseudo-tumorale